

**PATIENT**

Zoe Bellizzi

**PRESENTING CLINICAL SIGNS**

History: Grade II-III/VI systolic murmur; no clinical signs. BP: 125-130mmHg.

**SPECIES**

Canine

**ECHOCARDIOGRAM FINDINGS**

2D, m-mode, color flow and Doppler imaging is available.

**Left ventricle:** The LV diameter is normal with adequate myocardial function. LV wall thicknesses are normal.

**BREED**

Dachshund

**Left atrium:** The left atrium is minimally dilated.

**Mitral valve:** The mitral valve is mildly thickened with no prolapse into the left atrial lumen. Mild eccentric mitral regurgitation with a normal velocity.

**SEX**

Female Spayed

**Aortic valve/aorta:** The aortic valve is normal in morphology and mobility. Normal aortic outflow velocity; laminar flow. No aortic insufficiency.

**Right ventricle:** Normal right ventricular diameter and morphology indicating no overt evidence of pulmonary arterial hypertension.

**AGE**

6 years

**Right atrium:** Normal RA dimension.

**Tricuspid valve:** The tricuspid valve appears thickened with septal prolapse and mild tricuspid regurgitation; borderline velocity.

**WEIGHT**

10lbs

**Pulmonic valve/pulmonary artery:** The pulmonic valve is normal in morphology and mobility. No pulmonic insufficiency. Normal RVOT velocity; laminar flow.

**Pericardium/other:** No pericardial or pleural effusion noted. No obvious cardiac masses.

**Heart rhythm:** ECG reveals a sinus rhythm with an average HR of 80bpm.

**2-Dimensional Measurements**

**Doppler Measurements**

**INTERPRETED BY**

Maggie Machen  
Lamy, DVM  
DACVIM (Cardiology)

Ao diam (cm)	1.4
LA diam (cm)	1.7
LA:Ao (Swe)	1.3
IVS thickness (cm)	0.66
LVID diastole (cm)	2.3
PW thickness (cm)	0.67
LVID systole (cm)	1.6
FS (%)	32

PV Vmax (m/s)	0.8
AoV Vmax (m/s)	1.2
MR Vmax (m/s)	5.7
TR Vmax (m/s)	2.7
TR PG (mmHg)	30

**IMAGING**

**PERFORMED BY**

Pamela Harrigan,  
RDCS

**INTERPRETATION OF THE FINDINGS**

The cause of the murmur is chronic degenerative valve disease causing mild mitral and tricuspid regurgitation. Lack of significant left atrial enlargement indicates the current risk for complication is low. Borderline pulmonary hypertension is noted which should be monitored going forward. No additional issues are noted in this study. Assessment of progression in the future will help predict long term prognosis, which is highly variable at this stage (B1).

**HOSPITAL NAME**

Rhode Island Animal  
Medical Center

**RECOMMENDATIONS**

- In an asymptomatic dog without significant left atrial enlargement, no cardiac medications are clearly indicated.
- Omega fatty acid supplementation and mild salt restriction may be of some long-term benefit.
- Anesthetic risk is considered mild if needed. Cardiac protective drug choices (opioid/benzodiazepine premedication, propofol or alfaxalone induction, isoflurane gas) are recommended. Pre-oxygenate for 5-10 minutes prior to induction. Monitor

**REFERRING VET**

Dr. Rogoff

**INVOICE**

23410

**DATE**

4/1/22



**PATIENT**

Zoe Bellizzi

for arrhythmias, hypotension, and hypoxia both intra and post-operatively and intervene as necessary. Mild IV fluid restriction is recommended to avoid fluid overload. Avoid heart rate stimulating drugs such as atropine unless clinically indicated.

**SPECIES**

Canine

- Monitor for development of a cough, labored breathing, exercise intolerance or collapse episodes.

**BREED**

Dachshund

**PLAN**

- Recommend conservative monitoring with a recheck echocardiogram in 6 months, sooner if any development of clinical signs.

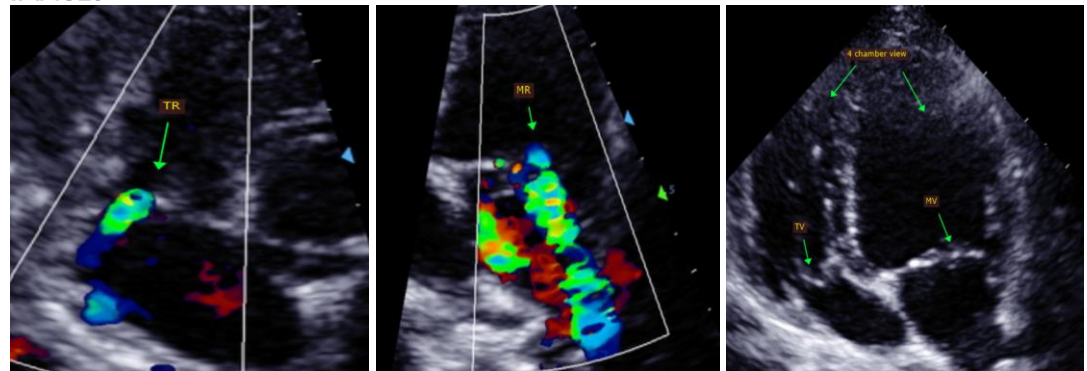
**SEX**

Female Spayed

**IMAGES**

**AGE**

6 years



**WEIGHT**

10lbs

**INTERPRETED BY**

Maggie Machen  
 Lamy, DVM  
 DACVIM (Cardiology)

The information and recommendations provided are based on the images presented by the referring veterinarian. No evaluation can be communicated regarding pathology that was not visible in the image/video clips provided.

**IMAGING**

**PERFORMED BY**

Pamela Harrigan,  
 RDCS

Thank you for this referral. This report was generated using transcription software, and minor dictation errors may be present. If the clinical or image interpretation does not parallel your findings or if I can be of any further assistance, please contact me.

**Maggie Machen Lamy, DVM**  
 Diplomat of the American College of Veterinary Internal Medicine (Cardiology)  
 info@sonopath.com

**HOSPITAL NAME**

Rhode Island Animal  
 Medical Center

**REFERRING VET**

Dr. Rogoff

**INVOICE**

23410

**DATE**

4/1/22